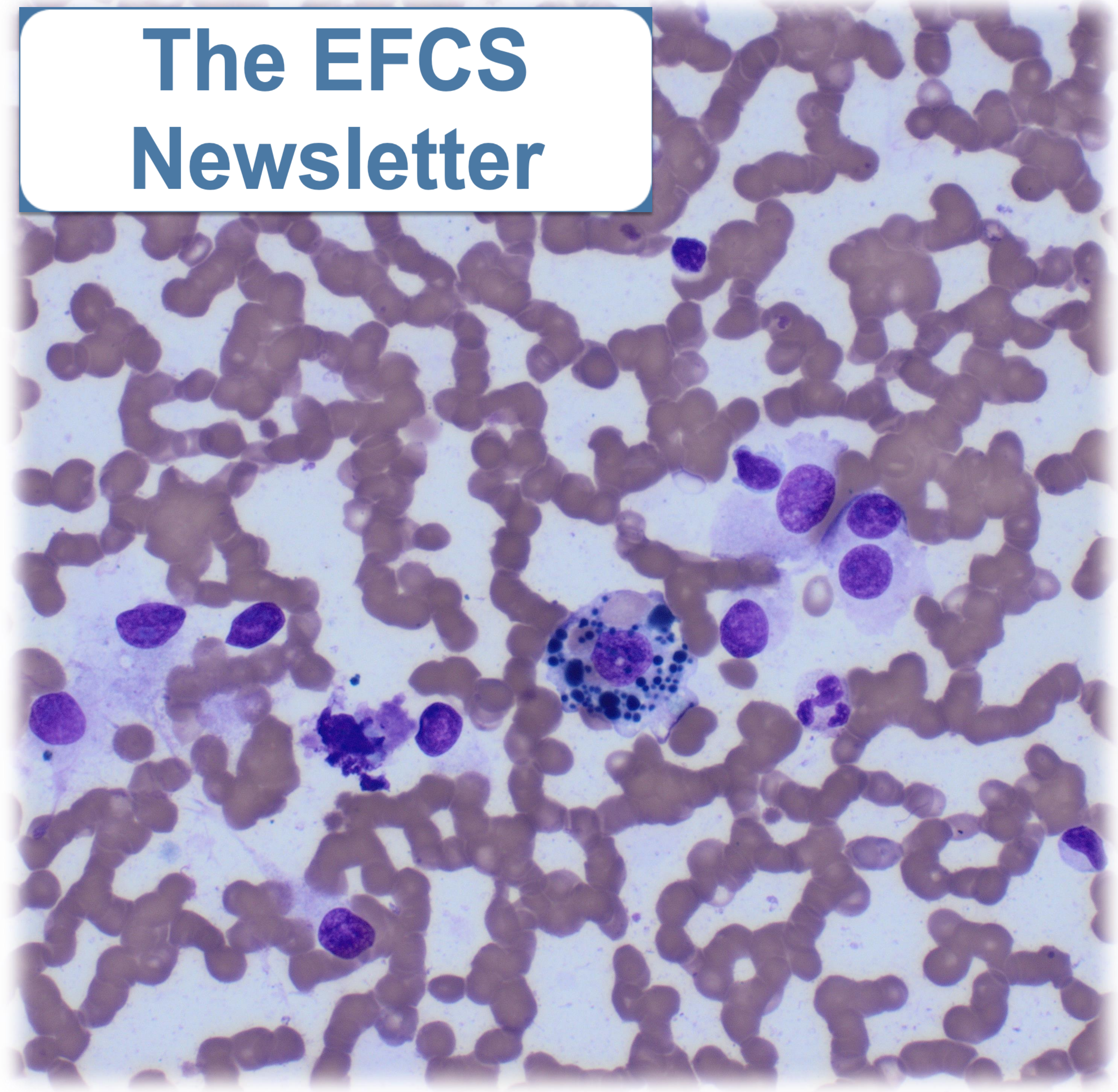




**EFCS**  
European Federation of  
Cytology Societies

# The EFCS Newsletter



## Issue 1/2022





# EFCS NEWSLETTER

## ISSUE 1/2022



**EFCS**  
European Federation of  
Cytology Societies

Dear Friends and Colleagues,

The new year brings us changes in EFCS Council Board. EFCS Residents and Young Pathologists Committee expanded and right now we have five members. Unfortunately, Ricardo resigned from his function (you can find his farewell on the next page). Together with Christina he was running some very important projects for EFCS and for young cytopathologists (e.g. this Newsletter). We would like to thank Ricardo for his efforts in making young cytopathologists more visible! Our new members are very enthusiastic, show great passion to cytopathology and will continue this work.

There are also a lot of changes in other EFCS Committees. Full list of EFCS Committees' members can be found on EFCS website (<https://www.efcs.eu/committees/>). We would like to thank the EFCS Council Board members who contributed to this issue and who will contribute in the future. We believe it is very important for European cytopathologists (not only young ones) to have access to news regarding our beloved field of pathology.

In this issue we would like to present the report from EFCS Secretary General, case challenges, reports from the past cytological events and announcements of upcoming ones, summary of major changes in the new edition of The Paris System for Reporting Urinary Cytopathology, inspiring interview with dr Amanda Herbert and a detailed presentation of the Cytodiagnostic Section of the Hungarian Society of Pathologists. We hope, that the last text would be the beginning of the series to let us learn more about national cytological societies.

We wish you a pleasant reading of this issue. Of course, as always, we are waiting for your feedback ([residentsyoung@efcs.eu](mailto:residentsyoung@efcs.eu)) and please do not forget about our Twitter accounts @CytologyEFCS and @efcsyoung.

Pawel Gajdzis  
*EFCS Residents and Young Pathologists Committee*

## In this issue:

**Message from the EFCS Secretary General** (page 4)

*Danijela Vrdoljak-Mozetič*

**Announcement of EFCS Tutorial 2022** (page 5)

*Giovanni Negri, Arrigo Capitanio*

**Announcement of EFCS Joint Webinar of Hellenic and Croatian Societies of Clinical Cytology** (page 6)

*Webinar organising committee*

**QUATE exam in Zagreb report** (page 7)

*Sandra Moslovac*

**Report: IAP Winter Course Cytopathology** (page 9)

*Marianne Engels*

**Case challenges!** (page 11)

*Marianne Engels*

**What's new in The Paris System 2.0?** (page 16)

*Ashish Chandra*

**Interview with dr Amanda Herbert** (page 17)

*Despina Argyropoulou*

**Introducing the Cytodiagnostic Section of the Hungarian Society of Pathologists** (page 19)

*István Kovács*



# EFCS NEWSLETTER

## ISSUE 1/2022



**EFCS**  
European Federation of  
Cytology Societies

Dear friends,  
Dear EFCS community,

In 2018, under the leadership of Beatrix Cochand-Priollet, the EFCS demonstrated great commitment in developing a strategy to bring the federation closer to its younger members - the community of European cytology residents and young cytopathologists. The creation of a Residents & Young Cytopathologists Committee (in short, Young EFCS - YEFCS) came as a natural step of that strategy. And what a good decision this was!

Thanks to the work of this committee, the EFCS now has a Newsletter, a Twitter account, regular YEFCS sessions in the European Congress of Cytology, and other projects under development – and trust me, they are tremendous!

With the intention of going forward in this “investment in the younger generations”, the new EFCS Council Board, under the leadership of Danijela Vrdoljak-Mozetič, has decided to expand the YEFCS committee, with 5 fully dedicated and highly competent members. And I could not be happier! In the upcoming future, the YEFCS will surely strengthen, improve, and expand the work that has been done over the past 3 years, helping the EFCS reaching new heights!

It is now up to you (readers of this newsletter) to enjoy, be involved, share and spread the YEFCS work and activities among your colleagues and residents. Do not miss out this opportunity! Get involved and be a part of this growing section of EFCS!

Last but not least, I would like to finish this message by publicly and deeply thanking Beatrix, Fernando, Christina, Danijela and all the remaining members of the EFCS Council Board for their friendship, help, time, and patience. It has been a great responsibility and pleasure to work with you over the past 3 years, and to be directly involved in the creation and growth of what I believe will become one of the most important Committees of the EFCS. I hope I did not let you down.

Best of luck to you all, and to the members of the current YEFCS – Christina, Pawel, Damjana, Despina, and Istvan. I am sure you will thrive!

Stay safe!

Muito obrigado

**Ricardo Veiga**  
*Former YEFCS chair*

**For more information about the EFCS, visit our website!**

**<https://www.efcs.eu/>**





# EFCS NEWSLETTER

## ISSUE 1/2022



**EFCS**  
European Federation of  
Cytology Societies

### Message from the EFCS Secretary General

Dear colleagues and friends,

Past several months were filled with intensive and interesting activities of the EFCS and new Council board. Educational website Eurocytology.eu has become the property of EFCS, the editor-in-chief is Beatrix Cochand-Priollet with IT assistance from Arrigo Capitanio. I am sure that the updated site will improve online education in cytology for cytopathologists and cytotechnologists. EFCS scientific projects are progressing well, some are already in the final stages, others in the execution or planning, and all are outstanding in their idea and multinational cooperation between EFCS member societies. The Young EFCS Committee with its enthusiastic new chair, dr Pawel Gajdzis, is a guarantee of the future of cytology and EFCS, and the proof is this newsletter which you are just reading. EFCS is preparing intensively for numerous scientific and professional cytology events during 2022. These are webinar on lymph node cytology in March, EEFCS Tutorial and QUATE exam in June in Trieste (more details in articles later in newsletter) and Cytopathology sessions in ECP in Basel in September. Moreover, I am proud to announce numerous participations of EFCS and European cytologists in IAC / ASC Congress in November 2022 in Baltimore, USA. Next European Cytology Congress will be organised in October 2023 in Hungary. Preparations are going excellent, and we are looking forward to sharing our experiences, knowledge, and scientific accomplishments, as well as meet and socialize face to face in the beautiful city of Budapest.

EFCS is a friendly, opened, and collegial association of all of us, European cytology enthusiasts. So, any suggestions, proposals and information on local / national cytological activities are welcome!

As I write these lines, we are faced with unbelievable human catastrophe. It is a fifth day of the invasion of the Russian army and the war in Ukraine and Europe. Terrible images and news alternate before our eyes, and anxiety and sadness rule our hearts. I believe we all share those feelings. I want this mindless war to end, for Ukrainian people to return to a normal, peaceful life filled with the joy. I do fully support Ukrainian colleagues and people, in moral and every other aspect. I sincerely hope that peace will soon prevail.

**Danijela Vrdoljak-Mozetič**  
February 28th 2022



# EFCS NEWSLETTER

## ISSUE 1/2022



**EFCS**  
European Federation of  
Cytology Societies

### **The 13th Annual EFCS Tutorial will be held in Trieste, Italy, June 13-17, 2022.**

Due to the coronavirus pandemic, the last year EFCS Tutorial had to be replaced by a digital edition. The event has been an exciting success, and we had a highly positive feedback. The 2021 digital edition of the Tutorial had however to be compressed in two days, and many participants missed the opportunity to directly interact with the tutors and other colleagues of all around Europe. Moreover, although digital cytology will be indubitably the future of our discipline, working for a week at the microscope with exemplary glass slides is still the closest experience to the way we all work every day.

Thus, in Trieste 2022 we will resume the classical Tutorial format, which is based on on-site microscopy workshops and lectures covering the most important topics in cytopathology, including special techniques of diagnostic relevance. Main topics will be Thyroid, Serous Effusions, Pancreas, Urine, Lymphnode, Salivary Gland, Respiratory Tract, Breast and Gynecologic Cytology. Short lectures covering ROSE, digital and molecular Cytology will also be included. Moreover, after the experience with the virtual Tutorial 2021, we will add virtual slides to the classic format, which will be made available in advance to the participants, and discussed live at the end of each microscopy workshop. The event will be chaired again by Giovanni Negri, and co-chaired by Arrigo Capitanio. Local Host is Fabrizio Zanconati.

Continuing the tradition started with last year's Tutorial, the lectures will be recorded and will be available online for those who attended in the Tutorial in Trieste.

Of course, in spite of the recently more optimistic news about the coronavirus and although we will do all what is possible to organize an on-site event, we cannot foresee the evolution of the pandemic. Should the on-site event be impossible, we will switch to a virtual tutorial and let participants know as soon as possible.

We are confident that the EFCS Annual Tutorial will give again the possibility to cytopathologists and cytotechnicians to participate at an event with high educative and practical value, held by renowned European tutors. A week of full immersion in the world of cytology, together with participants of all around Europe, sharing cytological knowledge and the sun, culture and food of Italy!

**Giovanni Negri, Arrigo Capitanio**  
*EFCS Educational Committee*

*Visit our website for more information about EFCS Tutorial:*  
<https://www.efcs.eu/13th-annual-efcs-tutorial/>





We would like to inform you about the Webinar Lymph Node Cytology on Friday March 18th from 14:30-17:30 (Athens time). The Hellenic and the Croatian Societies of Clinical Cytology together with the European Federation of Cytology Societies (EFCS) are organising this FREE webinar to share experience and knowledge between both countries and invite all specialists involved in the field of Cytology throughout Europe and World to join.

Fine-needle aspiration cytology is widely used for the diagnosis and management of patients presenting lymphadenopathy, as it is a rapid, simple, reliable, minimally invasive, and cost-effective procedure. Ancillary techniques such as immunocytochemistry can give a lot of information for the diagnosis of reactive changes, benign/malignant lesions or a metastatic disease recognising the site of primary, avoiding unnecessary surgeries. Furthermore, the addition of immunophenotyping with flow cytometry they are now considered necessary techniques for the recognition and classification of lymphoid neoplasms.

The webinar consists of two parts:

- 1) Two lectures by expert Cytopathologists on Benign lymphadenopathies/low grade lymphomas and High grade NHL/Hodgkin lymphoma, followed by discussion.
- 2) The diagnostic approach and algorithm of interesting Case Reports (primary and metastatic) with lymph node enlargement will be presented by young and expert Cytopathologists, followed by discussion as well.

At the following link you will find the Preliminary Program

<https://mdcongress.gr/event/webinar-lymph-node-cytology/>

At the following link you can register

[https://bluetree.events/client/Webinar\\_Lymph\\_Node\\_Cytology](https://bluetree.events/client/Webinar_Lymph_Node_Cytology)

#### ORGANISING COMMITTEE

Assist. Prof. **Danijela Vrdoljak-Mozetič**, MD, PhD, MIAC, Secretary General of the European Federation of Cytology Societies

**Maria Nasioutziki**, MD PhD MIAC, Aristotle University of Thessaloniki Greece, President of Hellenic Society of Clinical Cytology

**Niki Margari** MD PhD, General Secretary of Hellenic Society of Clinical Cytology

Assist. Prof. **Dinka Šundov**, MD, PhD, University Hospital Split Croatia, President of the Croatian Society of Clinical Cytology

Assist. Prof. **Tajana Štoos-Veić**, MD, PhD, MIAC, University Hospital Dubrava, Zagreb Croatia, Vice President of the Croatian Society of Clinical Cytology



### Report: EFCS QUATE aptitude test 2021

On Saturday, 6th of November 2021, QUATE aptitude test (Quality Assurance, Training and Examinations) took place at the Catholic University of Croatia in Zagreb, Croatia.

The QUATE (Quality Assurance, Training and Examinations committee) Aptitude Test is an international exam organised by European Federation of Cytological Societies (EFCS) as one of the EFCS educational projects. It is an examination for cytotechnologists who fulfil the criteria for accreditation in their own countries designed to provide an objective assessment of a cytotechnologist's competence to screen conventional cervical smears or liquid based cytology samples and is available in traditional Papanicolaou, Surepath or Thinprep technologies.

The aim of the QUATE test is to objectively assess the ability and competence of cytoscreeners and cytotechnologists in Pap test screening. By passing the QUATE test, candidates obtain an EFCS certificate, which confirms their screening competence and contribute to achieving a high standard in the cervical cancer screening in their respective cytology laboratories.



The organizers of QUATE exam in Zagreb were Croatian Society for Clinical Cytology of the Croatian Medical Association, the QUATE Committee of the EFCS and the School of Medicine of the Catholic University of Croatia.

Education in cytotechnology in Croatia started in 1968/1969. After a period of training in a six-month course, during the 1981-1992, training in the form of a one-year program have been held under the auspices of the Ministry of Health and Social Welfare and the Croatian Society of Clinical Cytology of the Croatian Medical Association. Catholic University of Croatia was established in 2006 and the School of Medicine was founded in 2021.

*(continues on the next page)*



### Report: EFCS QUATE aptitude test 2021

Sixteen candidates attended the exam, 13 were from Croatia, one from Austria, one from Denmark and one from Russia.

It was a very successful QUATE test with a passing rate of just over 81%, which means that 13 out of 16 candidates passed the exam.

Apart from obtaining the EFCS certificate, candidates had the opportunity to exchange knowledge and professional experience.

The organization was impeccable, concerning the communication with candidates, theoretical MCQ part and microscopy slide. Venue was modern with adequate rooms, quality microscopes, facilities and refreshments. Our hosts from the Catholic University of Croatia were honoured to co-organize the exam and assist. prof. Vjekoslav Pajtl, Vice dean for postgraduate studies and teaching base relations, welcomed us cordially.

The organising committee of QUATE Croatia consisted of Dr Paul Cross and Mr. Allan Wilson from British Association for Cytopathology, Asst. Prof. Danijela Vrdoljak-Mozetič, MD, PhD, Secretary General of EFCS, President of the Croatian Society for Clinical Cytology of the Croatian Medical Association, Sandra Moslavac, MD, PhD, Deputy Director General of the Special Hospital AGRAM, School of Medicine of the Catholic University of Croatia and Leila Perković, MD, Special Hospital AGRAM.

The next QUATE examination will take place during 13th EFCS Tutorial in Trieste, Italy on Friday 17th of June 2022.

**Sandra Moslavac**  
*EFCS Educational Committee*





### Report: IAP Winter Course Cytopathology, January 21 – 22, 2022

On behalf of the IAP, German Division, an online-tutorial on cytopathology was organised in January 21 -22, 2022. 59 registered participants attended the meeting. Of these, 28 were from Germany, 31 from other countries including several European countries, but also Nepal, Vietnam, Singapur, Nigeria and Peru. Several bursaries have been granted by the Vladimir Totovic-Foundation and the IAP, German Division. (Application for travel grants from the Vladimir Totovic-Foundation can be made for other meetings as well, cf. <https://www.deutsches-stiftungszentrum.de/stiftungen/vladimir-totovic-stiftung-zur-f%C3%B6rderung-der-pathologie>.)



*The river Rhine in late afternoon is a nice view; just below the arrow lies the very modern building housing the Business & Training Center of the IAP in Bonn.*

The topics of the meeting were lung cytology, cytology of salivary glands, thyroid cytology and pancreas cytology, which were treated in lectures alternating with slide demonstrations and individual work using virtual microscopy. Lectures on molecular cytopathology of lung cancer, molecular diagnostics using cytology samples and on the new International System for Reporting Lung Cytology supplemented the program.

The speakers were renowned experts in the different fields of cytopathology. Faculty included Giancarlo Troncone, Longwen Chen, Beatrix Cochand-Priollet, Fernando Schmitt and Marianne Engels, who also organised the meeting.

*(continues on the next page)*



### Report: IAP Winter Course Cytopathology, January 21 – 22, 2022

The IAP, German Division, has implemented a platform for virtual microscopy several years ago which is used for tutorials on a regular basis. This proved to be invaluable in pandemic times. Three of the speakers provided scanned slides which were available to the participants during the meeting and for two weeks afterwards. In total more than 120 whole slide images on lung cytology and on cytology of salivary glands, thyroid and pancreas were provided. The thyroid workshop, presented by Beatrix Cochand-Priollet, the former Secretary General of the EFCS, was held using the renewed Eurocytology platform which worked excellent.



*The audience hall, which is equipped with excellent microscopes, is waiting for an on-site course ...*

It is to be hoped that another IAP Winter Course Cytopathology may take place once again in the well-equipped Training Center in Bonn/Germany, preferably as a hybrid event. Due to the efforts and the expertise of the team of the IAP, German Division, in Bonn the meeting took place without any technical problems.

**Marianne Engels**  
*EFCS Educational Committee Chair*





# Case Challenges!



## Case Challenges!

(Answers on the next page!)

1

Female patient, 75 years, pleural effusion. History of gastric carcinoma, diffuse type, G3.  
Fig. 1 and Fig. 2, pleural effusion, sediment smear, MGG, obj. 20x and 40x.

Fig. 1

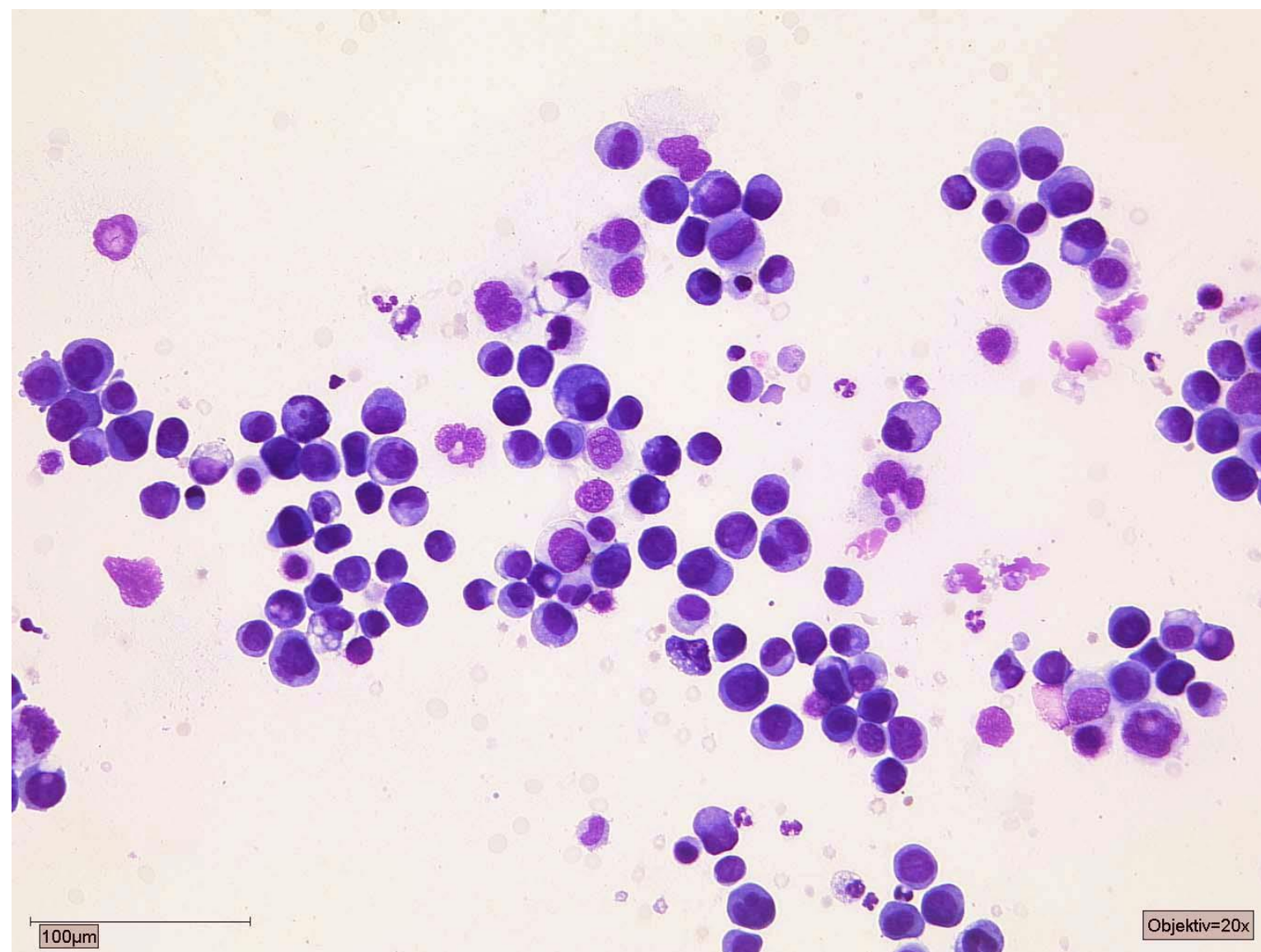
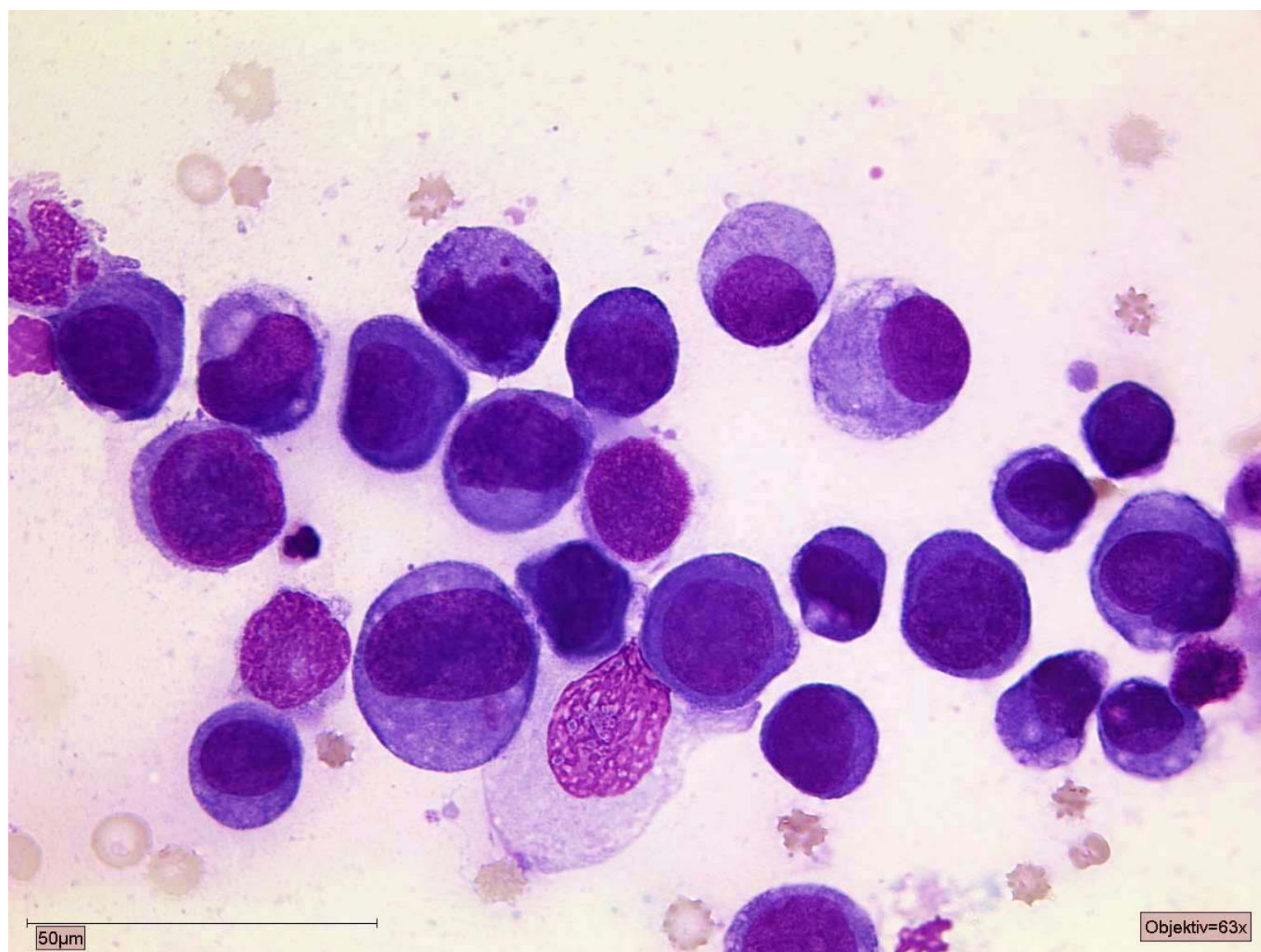


Fig. 2



### Questions

- Describe what you see.
- What does it represent?
- What is its significance?

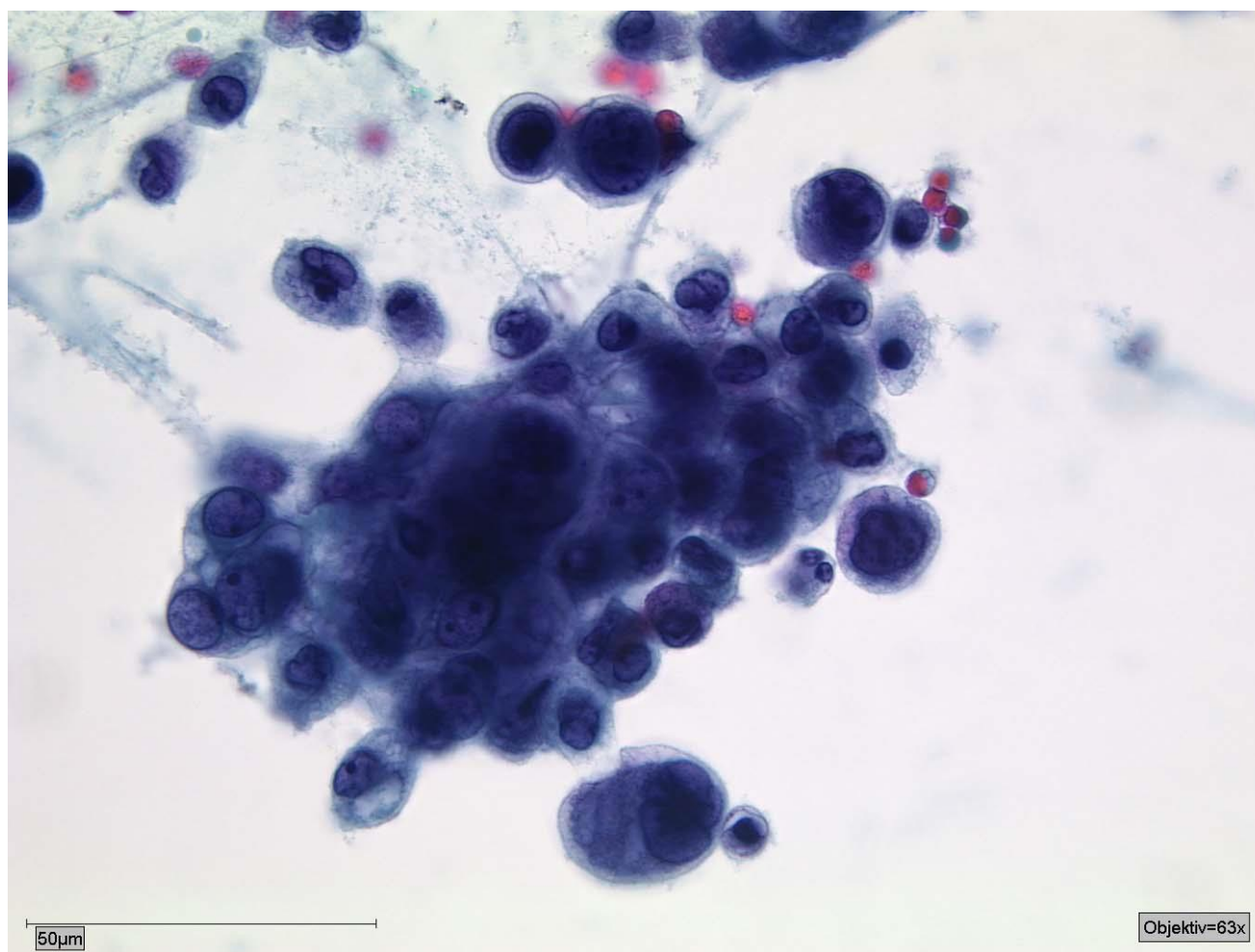


## ANSWERS

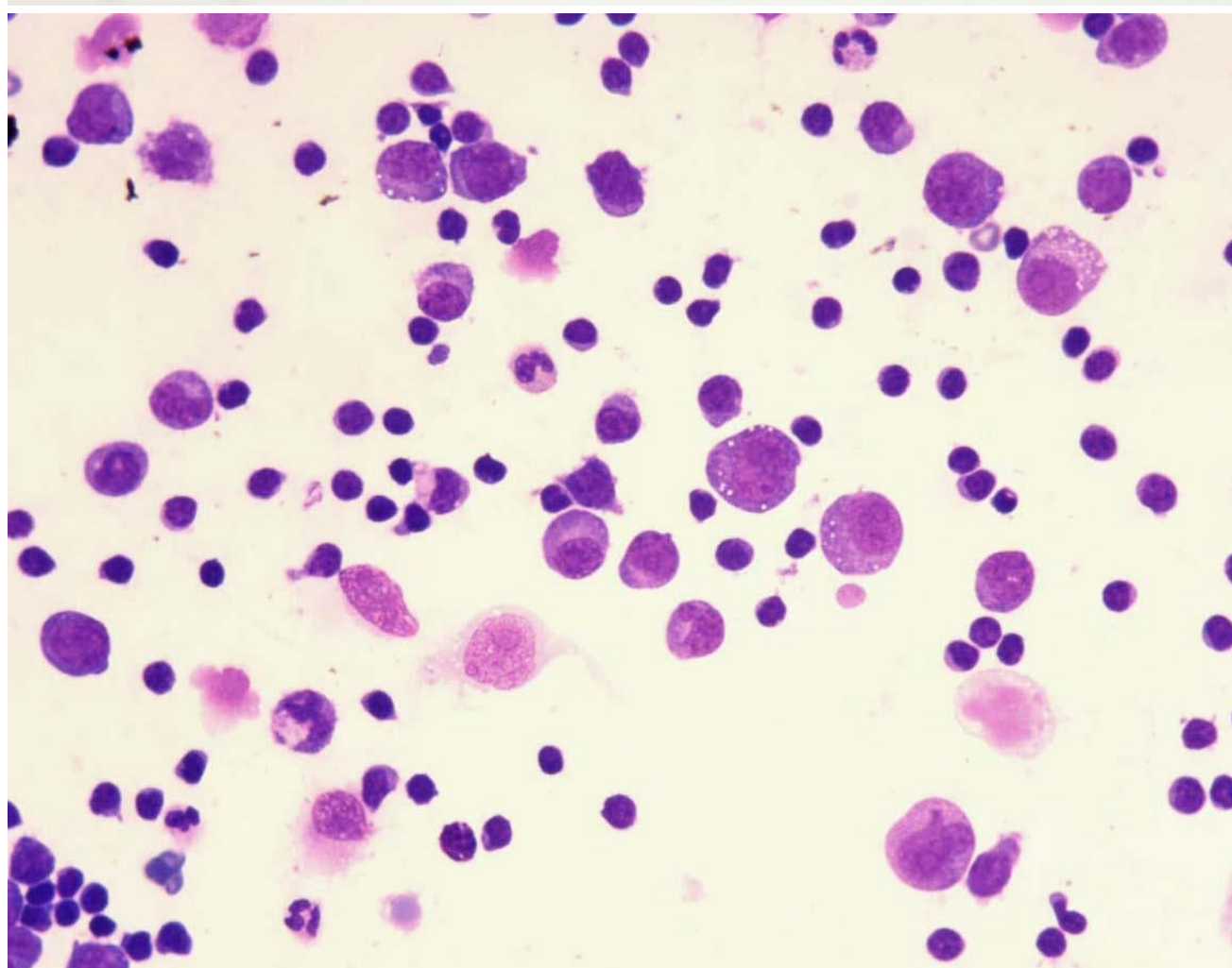
1

**Female patient, 75 years, pleural effusion. History of gastric carcinoma, diffuse type, G3.**

- a) Large, dissociated cells with large, dark nuclei and dense cytoplasm. Some neutrophils. No mesothelial cells.
- b) Malignant pleural effusion with cells of a non-small cell malignant tumor, consistent with gastric carcinoma.
- c) Differential diagnosis includes adenocarcinoma with single-cell pattern, other malignant solid tumor with single-cell pattern (for example malignant melanoma), and malignant lymphoma. If compact clusters of atypical cells are observed, in most cases it's a solid tumor. Cells of a malignant lymphoma may present with very different forms and sizes. In malignant lymphoma true cell clusters are never observed. In many cases immunochemistry is required for final diagnosis. In this case additive testing was restricted to BerEP4 which was positive in the tumor cells.



**Fig. 3**  
*Compact cluster of tumor cells. (Same case)*



**Fig. 4**  
*Large single cells of diffuse large B-cell lymphoma (DLBCL) in pleural effusion, some benign lymphocytes of medium size. (Other case, patient with DLBCL, immunoblastic variant)*



## Case Challenges!

(Answers on the next page!)

2

Male patient, 34 years, sputum (post bronchoscopy). In radiology pulmonary mass lesion, bronchoscopy was negative.  
Fig. 5 and fig. 6, sputum smear, Pap, obj. 40x and 100x.

Fig. 5

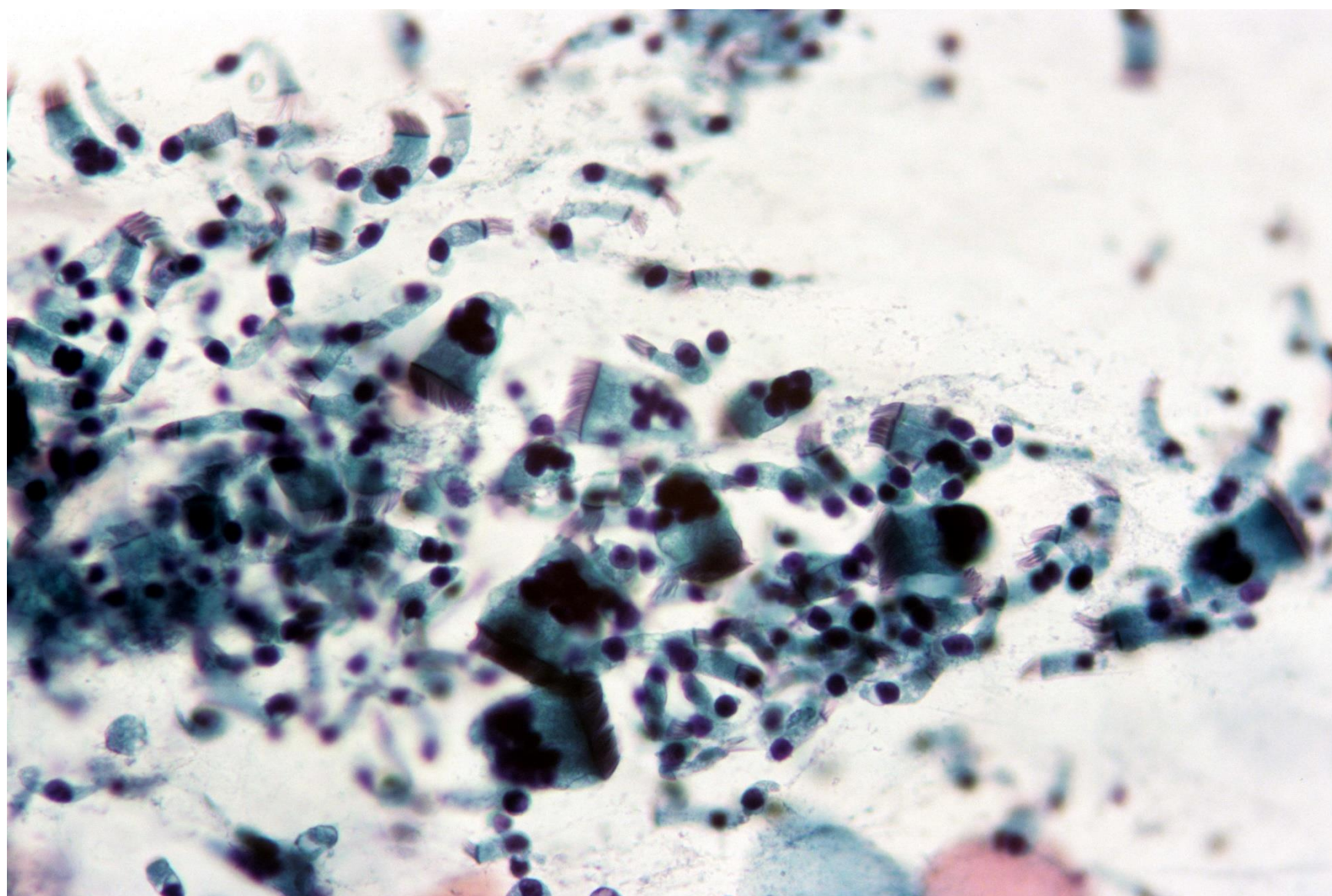
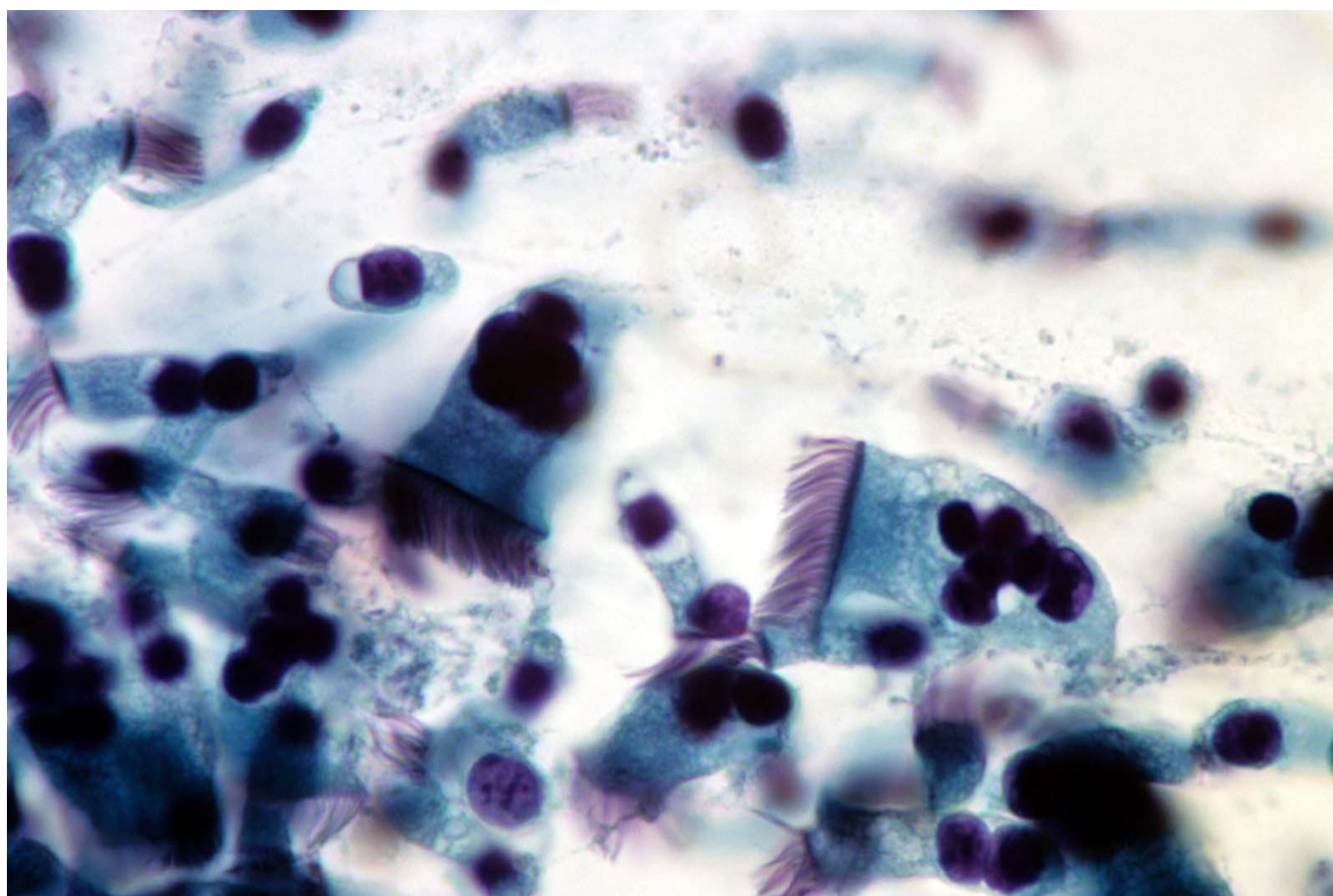


Fig. 6



### Questions

- Describe what you see.
- What does it represent?
- What is its significance?

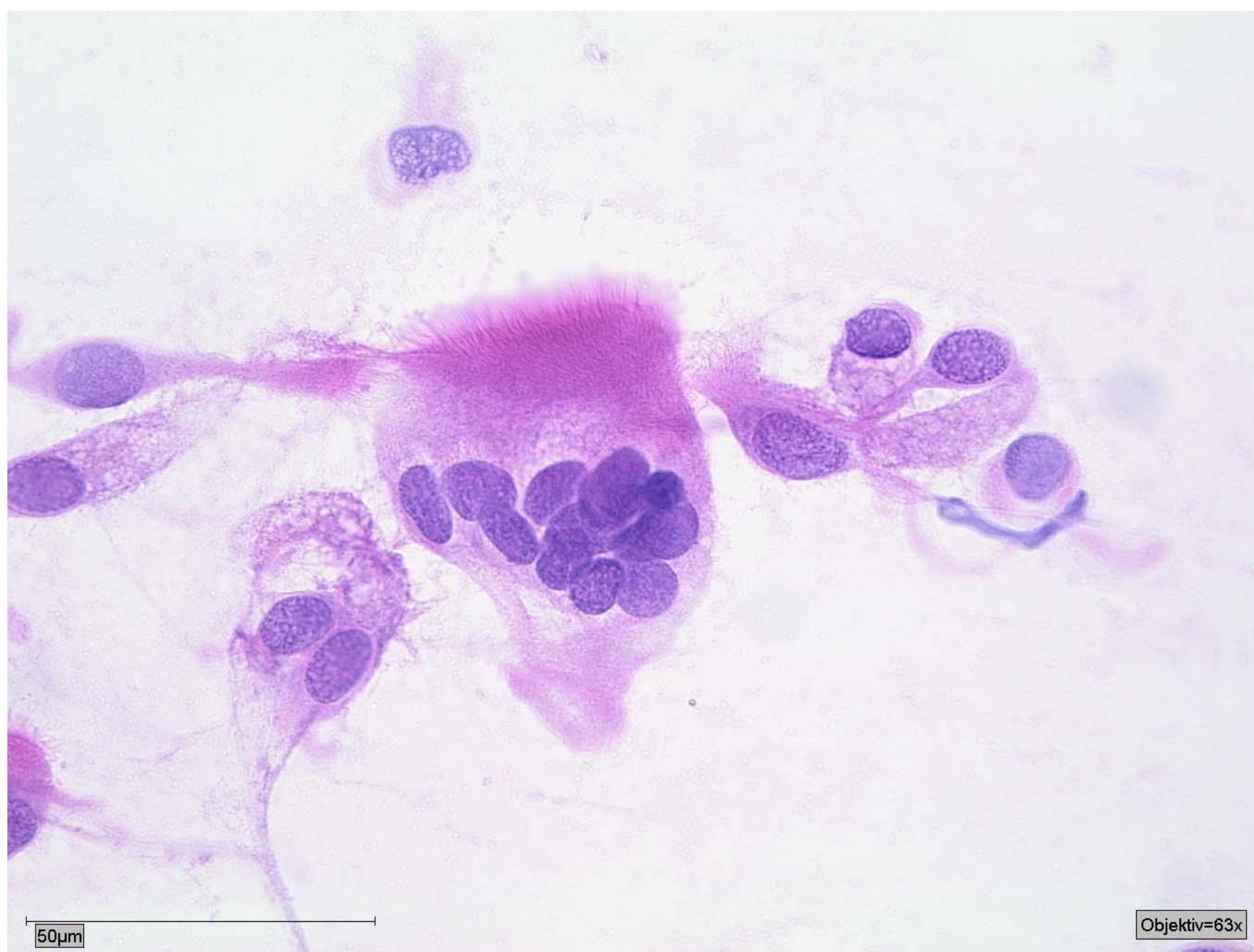

## ANSWERS

2

Male patient, 34 years, sputum (post bronchoscopy). In radiology pulmonary mass lesion, bronchoscopy was negative.

- a) Numerous ciliated columnar cells, many of them with two or more nuclei. The nuclei are small and even shaped, the terminal bar and the ciliae are intact. No malignant cells.
- b) Benign reactive change in respiratory epithelium.
- c) Multinucleated respiratory epithelial cells may occur as nonspecific reaction in various conditions, for example following bronchoscopy (as in this patient), in viral infection, after radiation or after exposure to toxic fumes.



**Fig. 7**  
*Large multinucleated  
bronchial epithelium.  
(Other case, TBNA smear,  
H&E, obj. 63x)*





# EFCS NEWSLETTER

## ISSUE 1/2022



**EFCS**  
European Federation of  
Cytology Societies

### What's new in The Paris System 2.0?

If you have been a trainee or a consultant in cytopathology within the last five years, you would already be familiar with the first edition of the Paris system for reporting urinary tract cytopathology.

This short update brings you the highlights of the recently published second edition of the book, now available both as ebook and paperback.

The single most valuable message of the Paris system is that the value of urine cytology lies in the detection of high grade urothelial carcinoma (HGUC). This message has not changed and neither have the key diagnostic criteria for the diagnosis of HGUC.

The key changes in the second edition are in the form of more detailed discussion and the addition of numerous new images, sample reports and up-to-date references. There are new chapters on the upper urinary tract and on Risk of high grade malignancy (ROHM) as a better indicator of clinical outcome than Risk of Malignancy (ROM).

One of the notable changes is the incorporation of Low Grade Urothelial Neoplasia (LGUN) within the Negative for HGUC (NHGUC) category. This strengthens the message that the focus of urinary cytopathology is on HGUC while LGUN remains a mainly cystoscopic finding, only occasionally detected on cytology due to their bland appearance and the rare finding of fibrovascular cores. Specimens where these features are seen should be reported as NHGUC with a comment stating that LGUN is possible and should be confirmed by cystoscopy and biopsy.

There is also a clarification offered that fibrovascular cores may also be seen in HGUC and that its established diagnostic criteria should be sought within these cores as well as in other groups and dispersed urothelial cells. The spectrum of N/C ratios, the observation of hypochromasia, degenerative changes and HGUC sub-types are also covered in this edition.

There is a streamlined discussion of atypical vs. benign-appearing urothelial tissue fragments, further characterization of degenerative changes in benign specimens and updated performance data for the NHGUC category.

If you are looking for illustrations of different preparations, you will not be disappointed as cytospin, ThinPrep and SurePath images have been significantly increased. Cytopreparatory methods including the role of cell blocks in selected cases have also been addressed.

There is a literature review on ancillary testing including new markers and assays including recent data on ancillary testing in the era of TPS and a new section on next-generation sequencing (NGS) in urinary cytology. The Cancer Genome Atlas molecular characterization has been incorporated into the pathogenesis of low-grade and high-grade urothelial carcinomas.

A number of research questions have been listed from all areas of urinary cytopathology in a separate section of the book and should give you ideas for suitable projects that may be of interest and relevance to your practice.

Significant changes in clinical guidelines for microscopic haematuria and reflex testing of atypical urine cytology as well as the expansion of surgical investigative techniques have been contributed to the book by the urologist co-authors.

TPS2.0 honours the late Dr Stefan Pambuccian through a touching tribute by the editors and by the inclusion of a chapter on the history of urinary cytology, one of his many illuminating works.

**Ashish Chandra**  
*EFCS Educational Committee*



## What a better way to learn than to share life experiences.

### Interview with **Dr Amanda Herbert**

by **Despina Argyropoulou**, *EFCS Residents and Young Pathologists Committee*



*Dr Amanda Herbert*

For this year's first EFCS Newsletter we interview **Dr Amanda Herbert**, cytopathology consultant at Guy's and St Thomas', dedicated to pulmonary and cervical cytology, President of the British Society for Clinical Cytology (2004-07), Editor-in-Chief of *Cytopathology* (2008-2014), Chairman of Cytopathology Subcommittee and Panel of Examiners of the Royal College of Pathologists (1993-97), member of the Advisory Committee for Cervical Screening in the Department of Health (1996-2003) and Computer Advisory Group for NHS Cervical Screening Programme, Co-Chair of Tutorials Committee for the European Federation of Cytology Societies (2008-2018), author of more than 100 research articles and the cervical cytology component of the online course *Eurocytology* (you can find it here: <https://www.eurocytology.eu/en/course/3>).

Dr. Herbert through graphics, quotes and maps introduced us, with a loving, humbled and passionate way, to her outstanding and dedicated life commitment to cytology practice, a 40-year path of experience!

### How did your love for cytology begin?

I had already developed a special interest in lung pathology while working on a radiology / pathology project using a machine (developed at Northwick Park Hospital) to inflate postmortem lungs. I was introduced to diagnostic (non-gynaecological) cytopathology by Dr Elizabeth A Hudson and Dr Alison Smithies, both of whom convinced me of its clinical importance – and earlier by Dr Dulcie Coleman at St Mary's Hospital and by occasionally attending Erica Wachtel's lectures at the Hammersmith where cytology was carried out in separate departments.

In my first few years at Southampton, I discovered that cervical cytology was undervalued (often described as a 'Cinderella' speciality) and lacking in quality control. The reasons were the relative rarity of cervical cancer at the time, the enormous gap between prevalence of the disease and the number of women screened and investigated – and the still-valid *Principles and practice of screening for disease*, Geneva: WHO (Wilson LMG, Junger G 1968). The first of their 10 principle being 'The condition sought should be an important health problem'. Joining the British Society for Clinical Cytology in the early 1980s, and being elected to its Council in 1984, put me in touch with experts in this field (including Elizabeth Hudson) and put my rapidly evolving local experience in the context of the UK at a time when the incidence of cervical cancer was increasing in young women.

(continues on the next page)



Visit [eurocytology.eu](https://www.eurocytology.eu) for cytology courses and  
virtual slides:

<https://www.eurocytology.eu>





# EFCS NEWSLETTER

## ISSUE 1/2022



EFCS  
European Federation of  
Cytology Societies

### **A remarkable moment during your cytology path that you would like to share.**

A truly remarkable moment was reviewing a previous Pap smear from a woman who had asked for an early repeat because her mother had died of cervical cancer. We had reported that smear as 'inflammatory changes' without even a recommendation for repeat. (I'm sure I had shown it to a consultant at the time!) The repeat smear was identical and showed extensive severe dyskaryosis (HSIL) – and her life was saved by excision of CIN3. Wow, what a mistake, which showed me the vital importance of quality control.

Key to improving our own practice was maintaining a record of women with abnormal cytology, high grade CIN and cervical cancer so that previous cytology could be critically reviewed. Reviewing the previous smears resulted in our recognising the types of abnormality that were at risk of being missed. It is hard to believe now that 'small cell dyskaryosis' could be misinterpreted as lymphocytes or endometrial cells; 'pale dyskaryosis' as reactive / 'atypical' immature metaplasia; glandular neoplasia as reactive endocervical cells; and syncytial sheets of CIN or CGIN overlooked as 'reactive' endocervical cells. We learnt this during the 1980s and early 1990s as young women were increasingly invited to be screened.

Slide reviews were regularly discussed with colposcopists and clinico-pathological meetings. This was vital, and remains so, to allow us all to understand each other's problems and limitations. It was also vital to include nurses and cytotechnologists in these reviews and discussions. I learnt early on at a teaching course in Manchester, that non-medical cytologists often knew more cervical cytology than pathologists. These multidisciplinary meetings also allowed us to develop protocols for avoiding over-treatment of mild and borderline abnormalities by concentrating on surveillance and slide review.

### **Favourite or the most memorable cytology diagnosis made?**

Perhaps telling a young man and his mother that an FNA that I had carried out on a lymph node in the neck looked benign when they had both been having sleepless nights thinking it was Hodgkin's lymphoma. I rang the surgeon and told him that I had, unusually, given my opinion to the patient and his mum. It reminded me that the departmental FNA clinic was a key reason for my moving to St Thomas'.

### **Most memorable moments Cytopathology has provided you?**

(On EFCS Tutorials): I especially enjoyed visiting Gabrijela Kocjan's spectacular house near Dubrovnik and the sea; visiting our hero George Papanicolaou's birthplace in Kimi; the surreal experience of being surrounded by Lego models in Denmark and the chance to visit Istanbul, which brought back memories of my first visit there in 1964!

### **Some take home messages?**

We need to concentrate on encouraging HPV vaccination, effectively screening those who chose not to be vaccinated, and continuing to develop expertise in diagnostic cytopathology including immediate diagnosis of FNAs. We should remember that no diagnostic tests (including HPV) work without active quality assurance and constant monitoring of test against outcome; that no test is perfect; and that Wilson & Junger's precepts still apply.

And we must remember to learn from our mistakes. May I thank the EFCS for asking me to contribute to this newsletter by looking back over my career. And may I offer my congratulations to the YEFCS and encourage them during these difficult, and now appalling, times.



## Introducing the Cytodiagnostic Section of the Hungarian Society of Pathologists

### The beginning

The discipline of cytology in Hungary grew out of clinical practice. From 1963, cytological examinations were regularly performed at the Broncho-Cytological Laboratory of János Kórház, Budapest by the pulmonologist Gábor Sassy-Dobray. He held broncho cytological training courses for local and foreign medical professionals, and with the contribution of onco-pathologist Lajos Döbrössy and gynecopathologist Miklós Bodó, he organised the 2nd European Cytology Congress in 1972<sup>1</sup>. By recognising the importance of pre-screening, the first Cytotechnologist Training Program was launched in 1972, under the leadership of Lajos Döbrössy. Until 1999, regularly organised national congresses were held by the Cytodiagnostic Section of the Hungarian Society of Oncologists that laid the foundation of the blooming and later fruitful cooperation with the Cytotechnologists' Society. In 1977 László Vass was the first to introduce aspiration cytology in Budapest, based on his two years professional experience in Sweden. In effort to provide continuous education in times of division, substitute tutorials were organised in the East for those who could not attend congresses arranged by the European Federation in the West. Such an event took place in Agárd, Hungary in 1980<sup>2</sup>, while eight years later Budapest was in line to host again a European Congress of Cytology. These events were equally enticing scientifically, and also meant to form a bridge between the West and the East and to openly state a positive political agenda.

In a gradual process lead by László Vass and Balázs Járay in close alliance with the cytotechnologists' community and also through the formation of the Cytologist Specialist Training Program, the practice of cytology shifted to the pathologist specialists by 1990, taking its place under the umbrella of the Hungarian Society of Pathologists. A couple of years later the UEMS Pathology Division justified this transition in harmony with the tendencies of realization of the professional responsibility in many European countries by that time. The Section managed to maintain a constantly evolving connection with fellow clinical fields, cytological scientific organizations and with our pathologist fellows who occasionally encountered and solved cytological problems. As the next step, the current legal form of the Cytodiagnostic Section was established after the 26th European Congress of Cytology, held in Budapest in 1999 with founding president, László Vass<sup>3</sup>.

### The Board and Members

The Cytodiagnostic Section elects a Board every four years. In 2021 Péter Pogány was elected president who is a leading professional in organising national cervical screening, a respected educator of cytotechnologists, pathology residents and cytopathologist trainees. The Board furthermore consists of the Secretary, Bence Nagy, five members – Mónika Erős, Balázs Járay, Ilona Kovács, Angéla Oszter, Eszter Székely - and a representative of the cytotechnologists, Liza Doroha. The Cytodiagnostic Section is proud to have cytotechnologists as full members.

(continues on the next page)





*Change of Board Presidency 2021*  
*Péter Pogány, Ilona Kovács*



*Board of 2016-2021*  
*From the left: Ilona Kovács, László Vass, Balázs Járay, Péter Pogány, Eszter Székely, Anikó Mágori, Csaba Tóth, Anita Matolcsi, Ágnes Pór*

### **Congresses, Courses, Quate**

Since 1999, national cytology congresses have taken place yearly, mostly near the beautiful Lake Balaton. The national congresses provide comprehensive, and intriguing scientific programmes with internationally renowned lecturers. In the year 2011 the Technology Transfer in Diagnostic Pathology 6th Central European Regional Meeting was held in Balatonfüred, organised by the Hungarian Division of IAP and hosted by cytologists Balázs Járay, Eszter Székely, Tamás Székely and chairman László Vass, featuring prominent international experts, including, but not limited to Philippe Vielh and Fernando Schmitt.

Simultaneously with the national congresses, CME accredited training courses have been held for participants. These courses are also parts of the Cytotechnologist Training Program and the postgraduate Diagnostic Cytology Training Program both registered in the Hungarian National Healthcare Service Centre.

QUATE exams were organised in 1999, 2001, 2010 and 2014. The Section translated exam materials into Hungarian, and ran pre-exam courses. The exams were under the professional supervision of the EFCS QUATE Committee.

### **Training Programs**

The Cytotechnologist Training Program takes 20 months, including a practical and a theoretical session, the latter mentioned above. The practical internship is centrally organised as well, where the training locations are determined with the involvement of a subspecialty cytologist specialist. Armed with the prerequisite histotechnician or analyst degree the participants acquire knowledge in the microscopic evaluation of diagnostic and screening smears of the cervix and the safe identification of negative smears. Furthermore, pre-evaluation of other cytodiagnostic preparations, consultative analysis of the results, application of quality assurance methods and archiving of materials are also included in the practical session. The fulfillment of both theoretical and practical requirements lets the participants take part in the complex specialty exam<sup>4</sup>.

(continues on the next page)





# EFCS NEWSLETTER

## ISSUE 1/2022



**EFCS**  
European Federation of  
Cytology Societies

Certain Hungarian universities of medical and health sciences offer various medical diagnostic analysis specialty courses (BSc in Medical Diagnostic Analysis) with the optional pathological analysis bachelor course (Pathologist's Assistance Specialization) that is under the care of the Cytodiagnostic Section as well. At the course, attendants master professional practice in cytopathology, macro-pathology, histochemistry, immunohistochemistry, and molecular pathology, learn administrative systematization and internal quality assurance techniques<sup>5</sup>. The graduate colleagues are granted a college degree thanks to the efforts and achievement of the Section, under the leadership of Past President Ilona Kovács.

In the Diagnostic Cytology Training Program participants with a pathologist specialty degree go through 24 months of training supervised, organised, and executed by the Section at accredited pathology departments. The trainees master diagnostic evaluation of gynaecological cytological, and non-gynecological cytological specimens, image-guided aspiration methods, basics in ultrasonography imaging and quality assurance. The knowledge base is facilitated by a two-week intensive basic cytology course and a two-week pre-exam course before the candidates can take part in a complex exam to acquire a degree<sup>6</sup>.

### **Every Day Practice**

The Section is committed in the practical and scientific cytopathological activities and the development of those on pathological grounds, by the release of newsletters and professional guides. On the basis of the extended 3rd edition (2013), Screening of Tumors - Quality Assurance Handbook and Methodological Guideline, written and edited by Döbrössy Lajos, László Vass and Miklós Bodó, the Handbook of Quality Assurance of Cytology Laboratories - Regarding Cervical Screening was released in August, 2017 by the workgroup of Melinda Hollósi, Ilona Kovács, Péter Pogány, and László Vass.

The Section is an established partner of QualiCont, an external quality assessment (EQA) provider<sup>7</sup>.

The Section has taken part in the Eurocytology project, and cooperates with the Turkish and the Romanian Societies of Cytology.

### **Save the Date**

At last, but not least: we are preparing for a new challenge: in 2023 the Section will host the 44th European Congress of Cytology. Take the opportunity and save the date: Budapest, 1-4 October 2023.

**István Kovács**

*EFCS Residents and Young Pathologists Committee*

Special thanks for the comments and advice from Ilona Kovács, Eszter Székely, Janina Kulka, László Vass, Miklós Bodó and Katalin Mátray.

Sources:

1. <https://www.arcanum.com/hu/online-kiadvanyok/Lexikonok-magyar-eletrajzi-lexikon-7428D/s-778D5/sassy-dobray-gabor-7798A/>
2. [EFCS Newsletter Issue 3/2021](#)
3. <https://pathology.hu/hu/szekciok/citodiagnosztikai-szekcio>
4. <https://pathology.hu/hu/hirek/1494/citologiai-szakaszsztens-kepzes>
5. [https://www.felvi.hu/felveteli/szakok\\_kepzesekek/szakleirasok/Szakleirasok/index.php/szak/79/szakleiras](https://www.felvi.hu/felveteli/szakok_kepzesekek/szakleirasok/Szakleirasok/index.php/szak/79/szakleiras)
6. <https://semmelweis.hu/aok/files/2018/10/Diagnosztikus-c%C3%ADtol%C3%B3gia.pdf>
7. [https://www.qualicont.com/qc/index\\_en.html](https://www.qualicont.com/qc/index_en.html)





**EFCS**  
European Federation of  
Cytology Societies

**Thank you for your time!**

**Please send your feedback to [residentsyoung@efcs.eu](mailto:residentsyoung@efcs.eu)**





EFCS  
European Federation of  
Cytology Societies

# The EFCS Newsletter



Expected Release Date of  
Next Issue:  
June 2022